

A 54 years old female patient was admitted to our outpatient clinic with a two months history of muscle spasms of her neck and pain radiating to the left upper extremity. Magnetic resonance imaging had shown a large left-sided paracentral disk herniation at the C6-C7 disc space (Figure 1). Neurological examination showed no obvious neurological deficit. She received conservative treatment including bed rest, rehabilitation, and analgesic drugs. After 13 months, requested by the patient, a second magnetic resonance imaging study showed resolution of the disc herniation.(Figure 2) Although the literature contains several reports about spontaneous regression of herniated lumbar disc without surgical intervention, that of phenomenon reported for herniated cervical level is rare, and such reports are few[1]. In conclusion, herniated intervertebral disc have the potential to spontaneously regress independently from the spine level. With further studies, determining the predictive signs for prognostic evaluation for spontaneous regression which would yield to conservative treatment would be beneficial.

#### Reference

1. Kobayashi N, Asamoto S, Doi H, Ikeda Y, Matusmoto K. Spontaneous regression of herniated cervical disc. The Spine Journal 2003(3): 171-3.

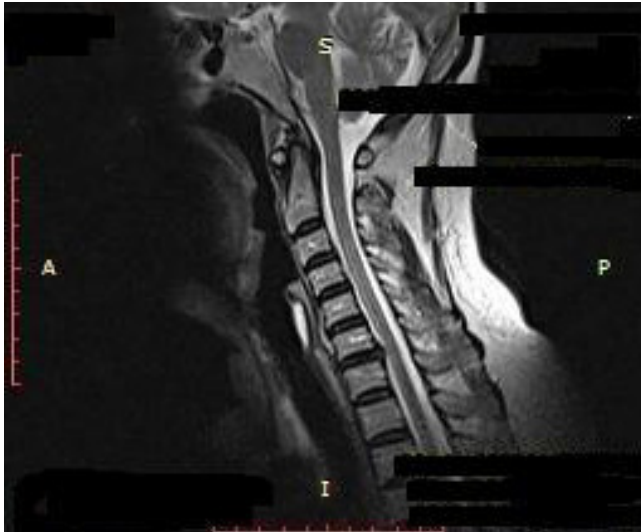


Figure 1. Sagittal T2-weighted image of the initial magnetic resonance imaging study reveals a large disc herniation at the C6-C7 disc space.

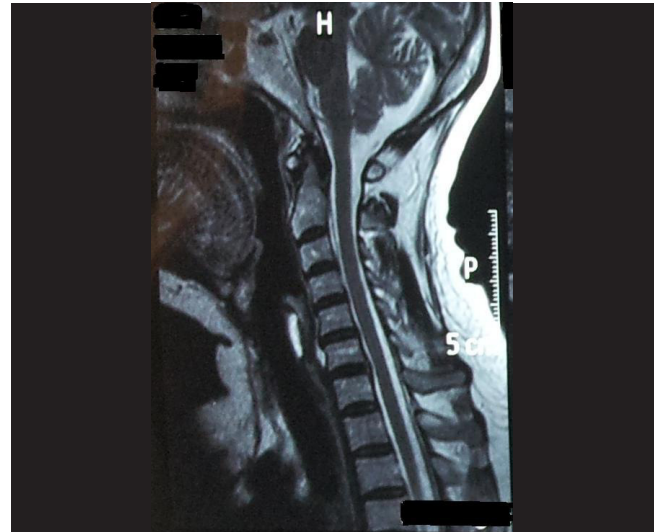


Figure 2. Second magnetic resonance imaging study showed regression of the disc herniation.